



ILLiad TN: 422137

Journal Title: Surg Laparosc Endosc Percutan
Tech.

Volume: 12

Issue: 3

Month/Year: June 2002

Pages: 195-8

Article Author: Gorecki

Article Title: Diognostic and Theroputic
Laporoscopy

Imprint:

ISSN 1530-4515

Call #: P

LD NUMBER:

Item #:

PATRON TYPE: Other

CUSTOMER HAS REQUESTED:

Carol Brown (cbrown)
1050 East South Temple
SALT LAKE CITY, UT 84102

NOTE:
PMID: 12080264

OCT 4 2002

Diagnostic and Therapeutic Laparoscopy for Trauma: A Technique of Safe and Systematic Exploration

Piotr J. Gorecki, MD, Daniel Cottam, MD, L. D. George Angus, MD, and Gerald W. Shaftan

Summary: Laparoscopy has a limited role in the evaluation of a stable trauma patient. The main concern addressed in the literature is a significant potential for missed visceral injury and a minimal role for therapeutic application. We present a simple technique for systematic abdominal exploration for a suspected intraabdominal injury in a series of three consecutive trauma patients (two penetrating injuries, one blunt) at a level-one trauma center. Three 5-mm ports and a 30-degree laparoscope were used for exploration. Additional ports for retraction were used as needed for therapeutic procedures. All patients underwent complete exploration of the abdominal cavity. Therapeutic procedures consisted of suturing an intraperitoneal bladder rupture, draining a lacerated tail of the pancreas, and cauterizing an actively bleeding penetrating wound to the left lobe and caudate lobe of the liver. All patients experienced prompt and uncomplicated recovery. There were no missed injuries. The presented technique enables a systematic laparoscopic exploration of the abdomen, which follows the same principles as open exploration. The role of laparoscopy in the treatment of a stable trauma patient is likely to increase as more surgeons acquire advanced laparoscopic skills, and as systematic exploration techniques are used. **Key Words:** Laparoscopy—Advanced Laparoscopy—Exploratory Laparoscopy—Trauma.

The application of diagnostic laparoscopy in the treatment of the trauma patient is a known concept. In 1976, Gazzaniga et al. (1) described 37 diagnostic laparoscopic procedures for blunt and penetrating injuries to the abdomen. In his report, 14 patients avoided laparotomy, 17 patients underwent a therapeutic laparotomy following laparoscopy, and 6 patients had a negative laparotomy following laparoscopy. There was one missed injury in the laparoscopic group.

The development of modern laparoscopy over the last 10 years revitalized interest in minimally invasive techniques as a diagnostic tool in trauma cases. After the

initial enthusiasm with diagnostic laparoscopy, several studies cautioned trauma surgeons about its potential for missed injuries (2,3). Therapeutic application of laparoscopy in the management of intraabdominal injuries has not been advocated in the trauma literature (3), but several authors reported laparoscopic repair of simple intraabdominal injuries (4-6). On the other hand, therapeutic laparoscopy has been increasingly used for the management of the intraabdominal infection, which also may require systematic abdominal exploration (7).

MATERIALS AND METHODS

Between March and May of 2000, three consecutive stable trauma patients were explored and treated laparoscopically at a level-one trauma center, one with blunt trauma and two with penetrating trauma. The indication for laparoscopy in all patients was the presence of peritoneal signs.

Case 1

A 25-year-old restrained driver was brought to the emergency department after experiencing a head-on

Received September 4, 2001; revision received February 1, 2002; accepted February 15, 2002.

From the Department of Surgery (PJG), New York Methodist Hospital Brooklyn, New York; and the Department of Surgery (DC, LDGA, GWS), Nassau University Medical Center East Meadow, New York.

Address correspondence and reprint requests to Piotr J. Gorecki, M.D., New York Methodist Hospital Department of Surgery, 506 6th Street Brooklyn, NY 11215. Address electronic mail to: pgorecki@pol.net

Presented at 2001 SAGES meeting, St. Louis, Missouri.

collision. He was alert and awake with stable vital signs. Computed tomography (CT) of the abdomen revealed free intraperitoneal fluid and no evidence of visceral injury. A cystogram was performed, which did not demonstrate bladder injury. Increasing signs of peritoneal irritation prompted exploratory laparoscopy, which revealed a 4-cm rupture at the dome of the urinary bladder. The laceration was sutured in two layers by using an intracorporeal technique. Complete exploratory laparoscopy did not reveal any other visceral injury. His recovery was prompt and uneventful, and he was discharged home on the second postoperative day. The Foley catheter was removed 8 days after the operation.

Case 2

A 23-year-old man was brought to the emergency department with an actively bleeding stab wound to the epigastric area and associated abdominal tenderness. His vital signs were stable. An exploratory laparoscopy revealed a through-and-through actively bleeding laceration to the left lobe and caudate lobe of the liver. About 300 mL of hemoperitoneum was evacuated, and hemostasis was obtained by using electrocautery. Complete laparoscopic exploration was conducted and did not reveal injury to the portal structures. No other visceral injury was found. The patient left the hospital 3 hours after the operation. His subsequent recovery was uneventful.

Case 3

A 34-year-old obese female, a victim of domestic violence, was admitted with a stab wound to the lower back and signs of neck strangulation. Her vital signs were stable. A 2-cm stab wound was found at the left paramedian side of the lower back at L1. A CT scan of the abdomen revealed a small amount of free fluid and haziness of the tissue planes in the region of the tail of the pancreas and the splenic hilum. Increasing abdominal pain and tenderness prompted exploration. Five ports were used (Fig. 1). During laparoscopic exploration, 100 mL serosanguineous fluid was aspirated. Using a 5-mm ultrasonic dissector, the surgeon dissected the gastrocolic and gastrosplenic ligaments and exposed the pancreas. The posterior wall of the stomach and the gastroesophageal junction were examined, and there was no evidence of perforation. The inspection of the pancreas revealed a laceration in the tail of the pancreas surrounded by fibrinous exudate.

Violation of the main pancreatic duct was not suspected based on the location and degree of the injury. The body and tail of the pancreas were mobilized from their retroperitoneal attachments to enable examination

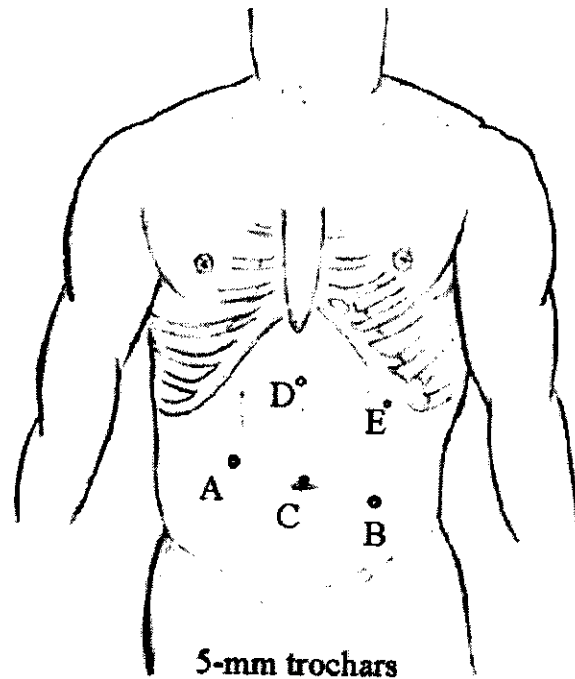


FIG. 1. Position of trocars during exploratory laparoscopy. A, B: operative ports. C: camera. D, E: optional trocars facilitating exploration and therapeutic interventions in the upper abdomen.

of the posterior aspect of the pancreas. A closed suction drain was placed in the retropancreatic space and the splenic hilum. Complete abdominal exploration did not reveal any other visceral injury. The postoperative course was uneventful, and the patient was discharged home 8 days after the operation.

Technique

Patients are placed on the operating table in a supine position, and general endotracheal anesthesia is given. If no abdominal distention or previous operation is evident, a Veress needle is inserted in the umbilicus, and pneumoperitoneum is obtained. A 5-mm 30-degree angled laparoscope is introduced via a 5-mm umbilical port. An initial brief visualization of the peritoneal cavity is done to rule out massive hemoperitoneum or obvious complex injuries. Two other 5-mm ports are placed in the right upper and left lower paramedian sites as shown in Figure 1.

The surgeon's initial position is on the patient's left side with the patient in the Trendelenburg tilt, which allows inspection of the pelvic structures, rectosigmoid, urinary bladder, both groins, and the iliac regions. Subsequently, the ileocecal junction is identified, and the right colon is inspected. Complete inspection of the small

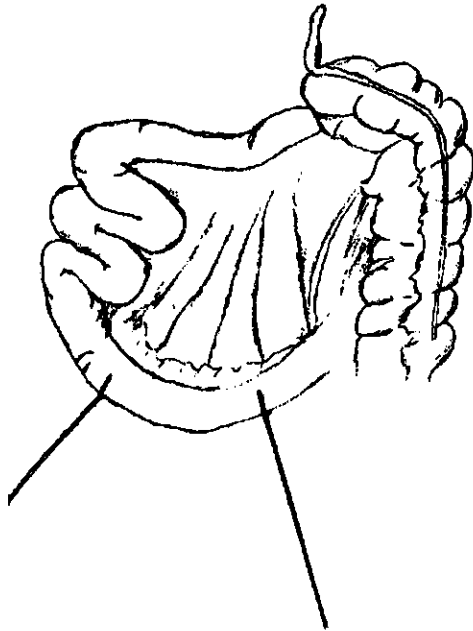


FIG. 2. Bowel is run in a hand-to-hand fashion. "Flipping" the segments of the intestine back and forth as it is run toward the ligament of Treitz allows the inspection of both sides of the bowel with its mesentery.

bowel is performed by using a hand-to-hand technique to "run the bowel" with a pair of atraumatic bowel graspers from the ileocecal valve to the middle of its length. "Flipping" the bowel back and forth as it is run proximally permits visualization of both mesenteric surfaces of each inspected segment (Fig. 2). The surgeon then changes his position to the patient's right to facilitate inspection of the small bowel from its middle length to the ligament of Treitz. The descending colon is also inspected from this position. Tilting the table laterally improves visualization of the flanks and mobilization of the colon as needed for complete exploration. Rotating the table into reversed Trendelenburg position allows easy access to the upper abdomen, the diaphragm, the spleen, the stomach, both lobes of the liver, and the transverse colon with its flexures. Inspection of the area of the gastroesophageal junction, posterior wall of the stomach, and the lesser sac including the pancreas requires placement of two additional ports for retraction and grasping by the assistant surgeon (Fig. 1). If no complex injuries are found and hemodynamic stability is assured, a focused therapeutic laparoscopy procedure, such as suturing or stapling of visceral perforation or cauterization or ligation of bleeding vessels, can follow, or strategic incision can be made depending on the nature of injury and surgeon's experience in the advanced laparoscopic techniques.

DISCUSSION

Diagnostic laparoscopy in the evaluation of abdominal trauma has been reported to be a sensitive tool for identification of intraabdominal injury and the need for exploratory laparotomy (3,8,9,10). In a review of 1,900 trauma patients who underwent laparoscopic evaluation for trauma, it was found that 63% of patients avoided laparotomy (3). Several authors reported a decreased complication rate, shorter length of hospital stay, and decreased costs when negative laparoscopy was compared with a negative or nontherapeutic laparotomy (11,12). Sosa et al. found that the 12.4% negative laparotomy rate for abdominal gunshot wounds was associated with a 22% morbidity rate and a mean hospital stay of 5.1 days. With the use of diagnostic laparoscopy in the similar group of patients, the authors were able to reduce the morbidity rate to 3% and the mean hospital stay to 1.4 days (12). Marks et al. reported a cost analysis of 14 patients who underwent a negative/nontherapeutic laparoscopy for penetrating abdominal trauma and 19 comparable patients who underwent a negative/nontherapeutic laparotomy. The overall cost of laparoscopy was significantly less and resulted in a savings of \$1,059 (U.S.) per patient as compared with laparotomy (11). Laparoscopy has also been found to be a sensitive tool

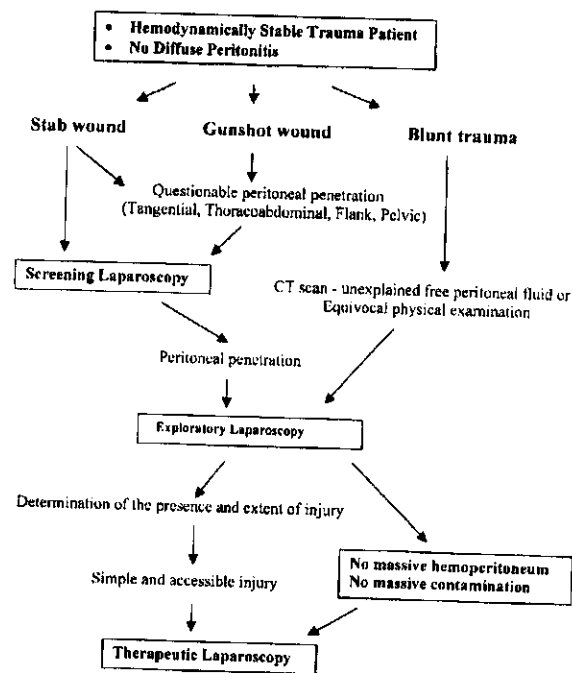


FIG. 3. Algorithm for potential applications of laparoscopy in trauma cases.

for detecting injuries to the diaphragm and peritoneal and diaphragmatic violation in penetrating abdominal and thoracoabdominal trauma cases (13,14). Therapeutic laparoscopy for trauma, however, remains a controversial subject (3). Based on the literature and our experience, an algorithm for potential applications for laparoscopy in trauma has been proposed (Fig. 3). We think that the described systematic approach for laparoscopic exploration follows all principles of open exploratory laparotomy for trauma. In the presented series, there were no missed injuries, and all treated patients made an uneventful recovery.

Therapeutic laparoscopic intervention in the form of suturing, stapling, resection, or diversion of visceral injury is feasible. Hemostasis of the bleeding solid organ or control of mesenteric bleeding can be attempted (15). The use of monopolar or bipolar cauterization, suture ligation, and application of Endoloop or vascular stapler can be considered based on the individual scenario and the surgeon's experience. Although access to retroperitoneal structures can be limited, the increasing success of elective laparoscopic surgery of the retroperitoneal organs such as the pancreas, adrenals, or kidneys makes therapeutic application of laparoscopy in this region a growing potential. At no point, however, can the principles of damage-control surgery (16) be put at risk by the use of minimally invasive techniques. No attempt to repair complex injuries laparoscopically should be made, since the potential benefit of the minimally invasive approach would not compensate for its shortcomings. The surgeon should have experience in treating trauma patients and should know his or her technical limitations for advanced laparoscopic interventions. Laparotomy or a smaller "strategic incision" should be performed if, at any point, the laparoscopic technique would compromise the expedient trauma management.

CONCLUSIONS

Laparoscopic exploration for trauma in the hemodynamically stable patient can be safely performed. All principles of abdominal exploration for trauma can be

adhered to. Moreover, laparoscopy has potential for therapeutic intervention in selected patients. This is a small study focusing on a technique of systematic abdominal exploration for trauma using a laparoscopic technique; no other study is available. A multicenter prospective study is needed to determine the role for advanced laparoscopy in treating the stable trauma patient with suspected intraabdominal injury.

REFERENCES

1. Gazzaniga AB, Stanton WW, Barlett RH. Laparoscopy in the diagnosis of blunt and penetrating injuries to the abdomen. *Am J Surg* 1976;131:315-8.
2. Ivatury RR, Simon RJ, Stahl WM. A critical evaluation of laparoscopy in penetrating abdominal trauma. *J Trauma* 1993;34:822-8.
3. Villavicencio RT, Aucar JA. Analysis of laparoscopy in trauma. *J Am Coll Surg* 1999;189:11-20.
4. Poole GV, Thomae KR, Hauser CJ. Laparoscopy in trauma. *Surg Clin North Am* 1996;76:547-56.
5. Smith RS, Fry WR, Morabito DJ, et al. Therapeutic laparoscopy in trauma. *Am J Surg* 1995;170:632-7.
6. Zantut LF, Ivatury RR, Smith RS, et al. Diagnostic and therapeutic laparoscopy for penetrating abdominal trauma: a multicenter experience. *J Trauma* 1997;42:825-9.
7. Geis WP, Kim HC. Use of laparoscopy in the diagnosis and treatment of patients with surgical abdominal sepsis. *Surg Endosc* 1995;9:178-82.
8. Brant CP, Priebe PP, Jacobs DG. Potential of laparoscopy to reduce nontherapeutic trauma laparotomies. *Am Surg* 1994;60:416-20.
9. Fabian TC, Croce MA, Stewart RM, et al. A prospective analysis of diagnostic laparoscopy in trauma. *Ann Surg* 1993;217:557-64.
10. Hallfeldt KKJ, Trupka AW, Erhard J, et al. Emergency laparoscopy for abdominal stab wounds. *Surg Endosc* 1998;12:907-10.
11. Marks JM, Youngelman DF, Berk T. Cost analysis of diagnostic laparoscopy vs laparotomy in the evaluation of penetrating abdominal trauma. *Surg Endosc* 1997;11:272-6.
12. Sosa JL, Baker M, Puente I, et al. Negative laparotomy in abdominal gunshot wounds: potential impact of laparoscopy. *J Trauma* 1995;38:194-7.
13. Ertekin C, Onaran Y, Guloglu R, et al. The use of laparoscopy as a primary diagnostic and therapeutic method in penetrating wounds of lower thoracic region. *Surg Laparosc Endosc* 1998;8:26-9.
14. Ivatury RR, Simon RJ, Weksler B, et al. Laparoscopy in the evaluation of the intrathoracic abdomen after penetrating injury. *J Trauma* 1992;33:101-8.
15. Chen RJ, Fang JF, Lin BC, et al. Selective application of laparoscopy and fibrin glue in the failure of nonoperative management of blunt hepatic trauma. *J Trauma* 1998;44:691-5.
16. Hirshberg A, Mattox KL. "Damage control" in trauma surgery. *Br J Surg* 1993;80:1501-2.