



Indications and Operative Outcomes of Gastric Bypass Reversal

Hinali Zaveri¹ · Ramsey M. Dallal² · Daniel Cottam¹ · Amit Surve¹ · Susan Kartiko² ·
Fernando Bonnani³ · Austin Cottam¹ · Samuel Cottam¹

Published online: 16 February 2016
© Springer Science+Business Media New York 2016

Abstract

Background Roux-en-Y gastric bypass (RYGB) is one of the best-known and most commonly performed bariatric procedures. However, this procedure carries infrequent but serious long-term complications, which may require revisional procedures. This study reports the indications and outcomes of gastric bypass reversal that have not been described well in the literature.

Methods A multicenter retrospective study of 50 patients who underwent reversal of RYGB conducted between 2006 and 2015 was reviewed to describe the usual indications and outcomes of gastric bypass reversal surgeries.

Results Of 50 patients, 7 (14 %) were males and 43 (86 %) were females. The mean age of the patient population was 40.4 ± 11.6 years (range 19–66). Reasons for reversal included anastomotic ulcers ($n=27$), anastomotic complications ($n=9$), malnutrition ($n=2$), and functional disorder ($n=12$). The mean BMI before the reversal was 29 ± 9.4 kg/m² (range 16–60). The mean time between the primary procedure and reversal was 60 ± 65.5 months (range 2–300). Fourteen of the reversals were done via laparotomy. Mean hospital stay was 8.4 ± 7.3 days (range 3–34 days). There was no peri-operative death 30 days after reversal. Following gastric bypass reversal, 92.6 % ($n=25$) of the patient population had resolution from ulcers, 77.8 % ($n=7$) of the patient population had resolution from anatomic complications, 100 % ($n=2$) of the patient population had resolution from malnutrition, and 66.7 % ($n=8$) of the patient population had resolution from functional disorders.

Conclusions Gastric bypass reversal is a reasonable and safe treatment for complications arising from the GBP surgery. A laparoscopic approach is feasible in select patients.

✉ Daniel Cottam
drdanielcottam@yahoo.com

Hinali Zaveri
hinalizaveri88@gmail.com

Ramsey M. Dallal
ramsey.dallal@gmail.com

Amit Surve
dramitksurve@gmail.com

Susan Kartiko
kartikos@einstein.edu

Fernando Bonnani
fbonanni@amh.org

Austin Cottam
austincottam94@yahoo.com

Samuel Cottam
samuelcottam@yahoo.com

Keywords Gastric bypass · Complication · Reversal · Bariatric revision · Indications · Ulcers · Malnutrition

Introduction

With the acceptance of surgery as the only effective long-term therapy for clinically severe obesity, surgeons have been called on to fix many of the complications that have resulted from the hundreds of thousands of procedures that have been

¹ Bariatric Medicine Institute, 1046 East 100 South, Salt Lake City, UT 84102, USA
² Einstein Healthcare Network, 60 Township Line Road, Elkins Park, PA 19027, USA
³ Abington Memorial Hospital, 225 Newtown Rd, 2nd Flr-Main Bldg, Warminster, PA 18974, USA

performed worldwide [1]. Among the many procedures that have been performed, the Roux-en-Y gastric bypass (RYGB) is the one with the most data concerning excess weight loss and resolution of comorbid conditions [2]. This procedure is often the revision procedure of choice for failures after other primary bariatric operations [3–5]. However, this procedure also has several life-threatening complications that have been reported in the literature that can result in the need for reversal of this common procedure [3, 6–12].

Complications following RYGB can be divided into early and late complications. Early complications include bleeding, infection, anastomotic leak, thromboembolic disease, and cardiopulmonary complications. These early complications rarely result in reversal of the gastric bypass and are not the focus of this paper.

Late complications include marginal ulcers, dumping syndrome, hiatal hernias, malnutrition, refractory hypoglycemia, nesidioblastosis, and hypocalcemia [13]. It has been documented that up to 25 % of bariatric patients will require a second operation for a complication at some point [14]. These late complications often times can only be solved by a reversal of the Roux en Y gastric bypass. There is very little literature available for patients and practitioners who are experiencing these problems [15].

In order to find as many of these procedures as possible, we combined the data from three tertiary referral programs to help address the weakness in the literature.

Materials and Methods

This is a multicenter retrospective study of 50 patients who underwent reversal of gastric bypass conducted between 2006 and 2015 at three centers chosen because of the relationships among the surgeons. At each institution, there was only one surgeon who performed the surgery.

Each institution had a systemic retrospective review of their prospectively kept database. Once a patient was identified, demographic data was obtained as well as relevant data, such as type of primary RYGB, indication for reversal, time period between RYGB and reversal, age at the time of reversal, technique of reversal, and type of revision (if applicable). Post-operative complications of the reversal procedure, follow-up time, and final outcomes were collected.

All three centers had a standard pre-operative workup which included an upper gastrointestinal endoscopy (EGD), upper gastrointestinal series (UGI), and a full set of nutritional labs. Each patient freely consented to undergo the revision of the RYGB as it was outlined to them.

All the three surgeons have used a lot of standardization of approach in doing these surgeries. However, not all cases were done exactly the same as there is variability both within practices and between practices.

Technique

Reversal to Normal Anatomy

In general, most of the time spent in these operations relates to the extent of adhesions present in the abdomen and whether or not the patient had open surgery in the past. When possible, the patient goes on a 2-week pre-operative diet to shrink the size of the liver. This helps create space between the liver and the stomach and aids in the difficult dissection in that area.

The next portion of the case is to find the caudate lobe and from there the hiatus. Then the surgeon is able to undermine the pouch and create enough space laterally to allow the passage of the stapler onto the gastric pouch. Once accomplished, the old gastrojejunal staple line is resected leaving a fresh staple line on the gastric pouch. This also frees up the Roux limb to be moved out of the way.

Next, the gastric remnant is mobilized off the pouch. Care must be taken to preserve as much blood supply as possible to prevent gastric remnant death. This usually means that the lesser curve must be left alone and as many of the gastroepiploic vessels should be preserved as possible. Too much dissection of the lesser curve or gastroepiploic vessels can result in remnant death.

Once the fundus is mobilized from the pouch, it is generally excised as the authors believe that leaving it intact would result in weight regain by giving the patients back their receptive relaxation based on the data by Cummings [16–18]. However, this is not always possible depending on the adhesions and the anatomy of the pouch and remnant.

The next part of the case is the excision of the Roux limb. We generally do not excise all the Roux limb and leave approximately 15 to 20 cm of Roux limb. This also prevents a lengthy dissection and reconstruction of the jejuno-jejunosomy. At the same time, 15 to 20 cm of roux limb will not give anyone bacterial overgrowth.

The most difficult part of the case relates to the creation of the gastro-gastrostomy. While a dogmatic one size fits all approach may be ideal, in reality the use of three different techniques, an end-to-end anastomosis (EEA) technique, a GIA technique of half stapled and half hand sewn, and a totally hand sewn technique were needed to complete the gastro-gastrostomy between the pouch and the body of the stomach. In general, an EEA technique, as described by Gagner, is the easiest to perform [19]. However, it is not always possible to do this as sometimes the remnant or pouch will not lend itself to a 25-mm EEA with an Orvil (Covidien) technique. In these cases, the technique chosen was based on the principle to leave the widest opening possible to reduce the chance of post-operative strictures. At the end of the case, typically there are two drains left, one next to the gastro-gastrostomy and one in the pelvis to catch any leaks that bypass the drain next to the

gastro-gastrostomy (Fig. 1). An upper GI series is always done on post-operative day 1.

Some patients were revised to a sleeve gastrectomy as described by Gagner [19] and others to a loop duodenal switch as described by Torres [20] for issues relating to weight.

Results

From 2006 to 2015, 50 patients underwent reversal of RYGB, 7 (14 %) were males and 43 (86 %) were females. Ten patients (20 %) were revised to SG at the end of the procedure. Four patients (8 %) were revised to duodenal switch (DS) at the end of the procedure. The mean age at the time of reversal was 40.4 ± 11.6 years (range 19–66). The mean BMI at the primary RYGB was 45.9 ± 6.3 kg/m² (range 36.8–61). Forty-five underwent laparoscopic RYGB and five underwent conventional laparotomy. The mean time interval between the primary RYGB and reversal was 60 ± 65.5 months (range 2–300). The mean BMI before the reversal was 29 ± 9.4 kg/m² (range 16–60).

Indications were divided into four major groups: ulcers, anatomical complications, malnutrition, and functional eating disorder (Fig. 2). Each patient had one or more indications for the reversal.

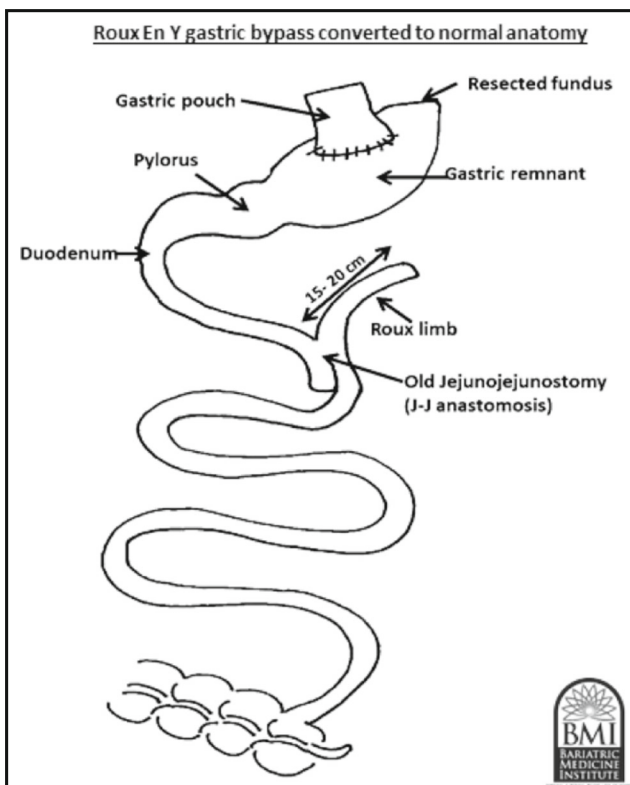


Fig. 1 The anatomy of gastrointestinal tract after RYGB reversal to normal anatomy

Recurrent Ulcer

An EGD was used to confirm the diagnosis of ulcers. Twenty-seven patients were diagnosed with chronic ulcers, requiring the RYGB reversal. Two patients had actively bleeding ulcers and required an emergent operation. They were immediately reversed. One patient was taking high-dose non-steroidal anti-inflammatory drugs (NSAIDs) for arthritis secondary to systemic lupus erythematous (SLE) syndrome. Maintaining RYGB was not feasible as NSAID use needed to continue. There were no ulcers or complaints of abdominal pain post reversal.

Five patients suffered from severe recurrent gastro-jejunal anastomosis (GJA) strictures because of an ulcer that failed to respond to conservative treatment. One patient underwent balloon dilation and had a perforation that had to be reversed emergently.

Five patients developed chronic marginal ulcers resulting in chronic pain and food intolerance.

Two patients had ulcers along with small bowel obstruction. They underwent RYGB reversal. However, post reversal, severe bile reflux, abdominal pain, and pyloric dysfunction developed. They underwent a number of revisions including Roux en-Y hepaticojejunostomy. Both eventually became symptom free.

The other 11 patients had only symptomatic ulcers and required RYGB reversal.

Anatomical Complications

Nine patients had anatomical complication as the indication for their RYGB reversal.

One patient had perforated gastric remnant and was reversed so that doctors could follow her ulcer disease endoscopically. One patient had an acutely ischemic roux limb and wanted the surgery reversed as did the patient that had 360° twist of a roux limb from adhesions causing chronic pain.

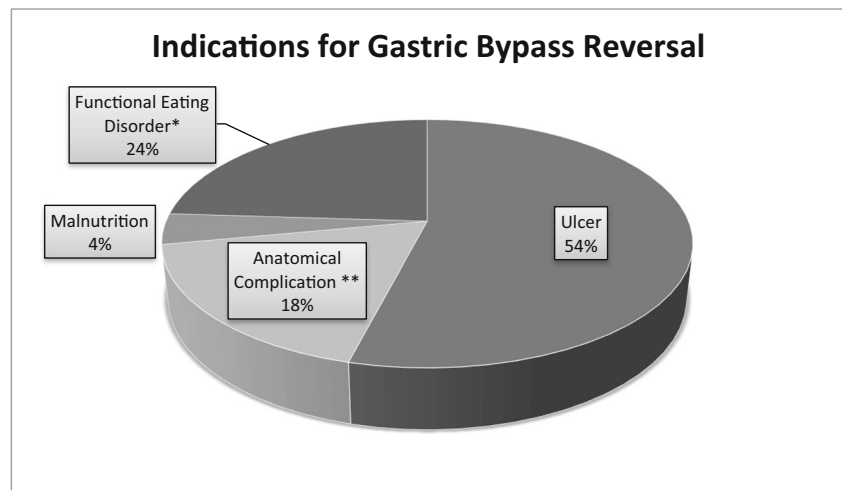
Two patients had small bowel obstructions from adhesions and wanted the surgery reversed. One patient had chronic low-grade bowel obstruction with persistent nausea, vomiting, and non-functional and dilated biliopancreatic limb.

One patient had intussusception and complained of severe abdominal pain and had to be reversed. Two patients had severe stricture at GJ junction and needed reversal.

Malnutrition

Two patients developed malnutrition following RYGB. One patient developed a near-obstructing carcinoid tumor in the terminal ileum after RYGB. The patient suffered chronic diarrhea and severe abdominal pain. The decision was made to proceed with the reversal along with resection of terminal

Fig. 2 Indications for gastric bypass reversal in percentage



*Dumping Syndrome, Roux Limb Stasis, Gastroparesis, Nausea, Vomiting.

**Small Bowel Obstruction, Bowel Ischemia, Severe Strictures, Twist of Roux Limb

ileum. Another patient developed severe vitamin deficiency with protein calorie malnutrition from unrelenting nausea and vomiting despite normal anatomy on UGI series and EGD. They required long-term TPN. Reversal totally eliminated the symptoms but did not reverse the symptoms related to her B1 deficiency.

Functional Disorders

Twelve patients had functional eating disorder as an indication for RYGB reversal. Two out of 12 patients had chronic abdominal pain of unknown origin. Because the anatomy of the RYGBP was normal, and another cause could not be identified, those patients were revised to a SG with complete resolution of their pain.

Three patients were diagnosed with severe incapacitating dumping syndrome; all three had immediate resolution of their symptoms after the reversal. One patient was diagnosed with roux limb stasis along with GERD. Diagnosis was confirmed by manometry along with a Bravo pH study which showed motility disturbances; a reversal with hiatal hernia repair solved his symptoms.

Four patients had intractable nausea and vomiting which was only solved with reversal.

One patient's mesentery had been unevenly divided during primary RYGB, resulting in a purple roux limb at the time of surgery. Years later, venous ectasia was seen on pathology. He came back to the clinic complaining of food intolerance and vomiting.

Thirty-six reversals were done laparoscopically while 14 were done by conventional open technique. Mean hospital stay was 8.4 ± 7.3 days (range 3–34 days). There were no 30-day peri-operative deaths after reversal. The peri-operative complications from the reversal are summarized in Table 1. Average follow-up time for all patients was 1 year.

The outcomes of gastric bypass reversal are shown in Table 2. However, there were six patients who did not follow up or refused to follow up completely and we could not evaluate the outcome of the reversal on those patients, and that is why their outcomes have been marked as unknown.

Discussion

RYGB failure due to medical complications related to the bypass is one of the most difficult issues faced by bariatric surgeons today. Since Himpens et al. [7] first reported a case of reversal of RYGB to normal anatomy, several reports have demonstrated the conversion of RYGB to normal anatomy [8, 10]. These case series are small and while informative do not provide the breadth of complications that occur after bypass. In this study, we present patients with different indications for failed RYGB who successfully underwent reversal of RYGB. Our early results indicate that gastric bypass reversal seems to eliminate most of the chronic complications related to gastric

Table 1 Peri-operative complications after RYGB Reversal

Complications	Number of patients (%)
GERD	5 (10 %)
Temporary food intolerance/gastroparesis	4 (8 %)
Strictures	4 (8 %)
Hernia	3 (6 %)
Diarrhea	3 (6 %)
Syncope	2 (4 %)
Peritonitis	1 (2 %)
Leak and abscess	1 (2 %)

Table 2 Outcome of gastric bypass reversal

	Ulcer (<i>n</i> = 27)	Malnutrition (<i>n</i> = 2)	Anatomical complications (<i>n</i> = 9)	Functional disorder (<i>n</i> = 12)
Resolved	25 (92.6 %)	2 (100 %)	7 (77.8 %)	8 (66.7 %)
Not resolved	0	0	1 (14.3 %)	1 (8.3 %)
Unknown	2 (7.4 %)	0	1 (14.3 %)	3 (25 %)

n number of cases

bypass, at least in short-term follow-up, with acceptable morbidity.

Problems related to RYGB like dumping syndrome must at first be treated by multidisciplinary counseling. These patients normally benefit from dietary measures [21]. However, some cases are refractory to diet measures and medical treatments. We had three such cases of dumping syndrome, which were resistant to standard medical care. Conversion of RYGB to normal anatomy is the last surgical option [7]. Evidence exists that slowing down the clearance of food from the gastric pouch may be efficient in the treatment of these conditions [22]. In our study, all three patients had resolution of dumping syndrome after the reversal.

It is documented that one third of the patients will develop roux limb stasis syndrome, characterized as nausea, vomiting, and postprandial vomiting [23]. Reversal of RYGB to SG has led to the resolution of their symptoms without significant weight regains [24].

Nutritional deterioration after RYGB is well documented in previous studies [25, 26]. It results from reduced oral intake or excessive losses secondary to reconfiguration of the GI tract. Retrospective analysis of patients who had undergone RYGB reveals micronutrient deficiencies, which in turn results in anemia in 20–49 % of these patients [27]. One of the reports from Korea suggests that the reason for malnutrition is not only attributable to prolonged bypass limb but also to inadequate food intake resulting from postprandial pain [9]. Thus, it becomes necessary to preserve at least a 3-m-long common channel to prevent malnutrition after RYGB. Surgeons should be careful to determine the length of the alimentary and biliopancreatic limbs to achieve a proper level of malabsorption while avoiding malnutrition. In our series, we were able to prevent malnutrition in 100 % of our patients after reversal.

In our study, the most common indication for reversal was recurrent anastomotic ulceration (*n* = 27, 54 %). Several mechanisms have been proposed to explain the pathophysiology of formation of these ulcers after RYGB. *Helicobacter Pylori* has been clearly implicated in the formation of ulcers in the gastric bypass population by weakening the mucosal protective barrier [28]. Mucosal injury could also result from the ingestion of non-steroidal anti-inflammatory drugs (NSAIDs), excessive alcohol consumption, or smoking. Only one of our patients who developed ulcers was on NSAIDs and none were smoking or had excessive alcohol consumption. Ulcer rates in

RYGB run 5 to 7 % and almost none of them are smoking or on NSAIDs [29].

Another postulation is that the acid produced in the remnant stomach in the presence of gastro-gastric fistula is not neutralized by food in contrast to normal anatomy [30]. This acid can reflux into the gastric pouch via the fistula and break down the mucosal integrity. Moreover, a delay in the release of pancreatic bicarbonates can allow the mucosa to be exposed to the gastric acid for a prolonged period of time. At the same time, bile reflux can also damage the mucosa, compounding the effects of the unbuffered acid [31]. Csendes et al. proposed other explanations, including the use of electrocautery, an element of ischemia, an inflammatory reaction to surgical sutures, and some association with partial anastomotic stricture also in response to an inflammatory reaction [32]. Late anastomotic ulcers typically occurring at 1 year or later after RYGB are often described as marginal ulcers in the majority of the literature. They can be caused by high gastric acid production due to a large gastric pouch, but none of the patients in this series had what surgeons considered a large gastric pouch [33, 34]. Recent data shows that the reoperation rates for ulcers are greatly increased.

All the surgeries were performed to preserve maximum vascularity of the gastric remnant. This is important since the remnant may have minimal vascularity, and the ability to assess this is usually compromised by scar tissue. While not in this series, the authors have seen two remnants die during surgery with seemingly adequate blood flow and what was believed to be minimal dissection.

The retrospective nature of the data collection is a limitation to this study. However, these 50 cases represent the tertiary referral pattern of the three study sites. As the reversal of RYGB is still very rare overall, this study is limited by small sample size. Yet, our sample size is much larger than all previously reported series [4, 6, 8, 10, 13, 24]. Another limitation relates to weight regain. We simply do not have long enough follow-up to make any meaningful statements about weight regain in these patients.

Conclusion

In our experience, gastric bypass reversal is a demanding operation that is unavoidable in many instances. Patients will

often present at inconvenient times with little work-up. Post-operatively, patients do very well but not universally so. It is important for surgeons to manage expectations. In most instances, these cases can be done laparoscopically.

Compliance with Ethical Standards

Conflict of Interest Daniel Cottam, the corresponding author of this report, is part of the speaker bureau for Medtronic and has been awarded a research grant by Medtronic for the study of duodenal switch.

All the other authors declare that they have no competing interests.

Statement of Human and Animal Rights All procedures performed in studies involving human participants were in accordance with the ethical standards of the institutional and/or national research committee and with the 1964 Helsinki Declaration and its later amendments or comparable ethical standards.

Since this is a retrospective study, the formal consent is not required for this type of study.

References

- Behms KE, Smith CD, Kelly KA, et al. Reoperative bariatric surgery: lessons learned to improve patient selection and results. *Ann Surg.* 1993;218:646–53.
- Buchwald H, Avidor Y, Braunwald E, et al. Bariatric surgery: a systematic review and meta-analysis. *JAMA.* 2004;292(14):1724–37.
- Gumbs AA, Pomp A, Gagner M. Revisional bariatric surgery for inadequate weight loss. *Obes Surg.* 2007;17:1137–45.
- Suter M, Ralea S, Millo P. Laparoscopic Roux-en-Y gastric bypass after failed vertical banded gastroplasty: a multicenter experience with 203 patients. *Obes Surg.* 2012;22:1554–61.
- Mognol P, Chosidow D, Marmuse JP. Laparoscopic conversion of laparoscopic gastric banding to Roux-en-Y gastric bypass: a review of 70 patients. *Obes Surg.* 2004;14:1349–53.
- Dapri G, Cadiere GB, Himpens J. Laparoscopic conversion of Roux-en-Y gastric bypass to distal gastric bypass for weight regain. *J Laparoendosc Adv Surg Tech.* 2011;21:19–23.
- Himpens J, Dapri G, Cadiere GB. Laparoscopic conversion of the gastric bypass into normal anatomy. *Obes Surg.* 2006;16:908–12.
- Vilallonga R, Vrande S, Himpens J. Laparoscopic reversal of RYGB into normal anatomy with or without sleeve gastrectomy. *Surg Endosc.* 2013;27:4640–8.
- Park JY, Kim YJ. Successful laparoscopic reversal of GBP in a patient with malnutrition. *Ann Surg Treat Res.* 2014;87(4):217–21.
- Dapri G, Cadiere GB, Himpens J. Laparoscopic reconversion of Roux-en-Y gastric bypass to original anatomy: technique and preliminary outcomes. *Obes Surg.* 2011;21:1289–95.
- Benotti PN, Forse RA. Safety and long term efficacy of revisional surgery in severe obesity. *Am J Surg.* 1996;172(3):232–5.
- Schwartz RW, Strodel WE, Simpsons WS, et al. Gastric bypass revision: lessons learned from 920 cases. *Surgery.* 1998;104(4):806–12.
- Moon RC, Frommelt A, Teixeira AF, Jawad MA. Indications and outcomes of reversal of Roux-en-Y gastric bypass. *Surg Obes Relat Dis.* 2015.
- Chousleb E, Patel S, Szomstein S, et al. Reasons and operative outcomes after reversal of gastric bypass and jejunoileal bypass. *Obes Surg.* 2012;22:1611–6.
- The longitudinal assessment of bariatric surgery (LABS) Consortium. Perioperative safety in longitudinal assessment of bariatric surgery. *N Engl J Med.* 2009;361:445–54.
- Cummings DE. Endocrine mechanisms mediating remission of diabetes after gastric bypass surgery. *Int J Obes.* 2009;33 Suppl 1: S33–S40.
- Frühbeck G, Diez Caballero A, Gil MJ. Fundus functionality and ghrelin concentrations after bariatric surgery. *N Engl J Med.* 2004;350(3):308–9.
- Kotidis EV, Koliakos G, Papavramidis TS, et al. The effect of biliopancreatic diversion with pylorus-preserving sleeve gastrectomy and duodenal switch on fasting ghrelin, leptin and adiponectin levels: is there a hormonal contribution to the weight-reducing effect of this procedure? *Obes Surg.* 2006;16:554–9.
- Parikh M, Pomp A, Gagner M. Laparoscopic conversion of failed gastric bypass to duodenal switch: technical considerations and preliminary outcomes. *Surg Obes Relat Dis.* 2007;3:611–8.
- Sanchez-Pernaute A, Rubio Herrera MA, Perez-Aguirre E, et al. Proximal duodenal-ileal end-to-side bypass with sleeve gastrectomy: proposed technique. *Obes Surg.* 2007;17:1614–8.
- Ukleja A. Dumping syndrome: pathophysiology and treatment. *Nutr Clin Pract.* 2005;20:517–25.
- Z'graggen K, Guweidhi A, Steffen R, et al. Severe recurrent hypoglycemia after gastric bypass. *Obes Surg.* 2008;18:981–8.
- Tu BL, Kelly KA. Surgical treatment of Roux stasis syndrome. *J Gastrointest Surg.* 1993;3:613–7.
- Simper SC, Erzinger JM, McKinlay RD, et al. Laparoscopic reversal of gastric bypass with sleeve gastrectomy for treatment of recurrent retrograde intussusception and Roux stasis syndrome. *Surg Obes Relat Dis.* 2010;6:684–8.
- Poitou Bernert C, Ciangura C, Coupaye M, et al. Nutritional deficiency after gastric bypass: diagnosis, prevention and treatment. *Diabetes Metab.* 2007;33:13–24.
- Dalcanale L, Oliveira CP, Faintuch J, et al. Long-term nutritional outcomes after gastric bypass. *Obes Surg.* 2010;20:181–7.
- Allied Health Sciences Section Ad Hoc Nutritional Committee, Aills L, Blankenship J, et al. Allied Health Nutritional Guidelines for the surgical weight loss patient. *Surg Obes Relat Dis.* 2008;4(5 Suppl):S73–S108.
- Cleator IGM, Rae A, Birmingham CL, et al. Ulcerogenesis following gastric procedures for obesity. *Obes Surg.* 1996;6(3):260–1.
- Dallal RM, Bailey LA. Ulcer disease after gastric bypass surgery. *Surg Obes Relat Dis.* 2006;2(4):455–9.
- Bjorkman DJ, Alexander JR, Simons MA. Perforated duodenal ulcer following gastric bypass surgery. *Am J Gastroenterol.* 1989;84(2):170–2.
- Iskandar ME, Chory FM, Goodman ER, et al. Diagnosis and management of perforated duodenal ulcers following Roux-en-Y gastric bypass: a report of two cases and review of the literature. *Case Rep Surg.* 2015;2015:353468.
- Csendes A, Burgos AM, Altuve J, et al. Incidence of marginal ulcer 1 month and 1 to 2 years after gastric bypass: a prospective consecutive endoscopic evaluation of 442 patients with morbid obesity. *Obes Surg.* 2009;19:135–8.
- Racu C, Mehran A. Marginal ulcers after Roux-en-Y gastric bypass: pain for the patient: pain for the surgeon. *Bariatric Times.* 2010;7(1):23–5.
- Patel RA, Brolin RE, Gandhi A. Revisional operations for marginal ulcers after Roux-en-Y gastric bypass. *Surg Obes Relat Dis.* 2009;5:317–22.