



ELSEVIER

Surgery for Obesity and Related Diseases ■ (2016) 00–00

SURGERY FOR OBESITY
AND RELATED DISEASES

Case report

Retrograde filling of the afferent limb as a cause of chronic nausea after single anastomosis loop duodenal switch

Amit Surve, M.D., Hinali Zaveri, M.D., Daniel Cottam, M.D.*

Bariatric Medicine Institute, Salt Lake City, Utah

Received November 30, 2015; revised January 14, 2016; accepted January 16, 2016

Keywords: Abdominal fullness; Nausea; Vomiting; Single anastomosis loop duodenal switch surgery; Management; Case report; Adhesions

Single anastomosis loop duodenal switch (SALDS) is a new surgical technique that was first described by Torres in Spain [1]. As this procedure is gaining in popularity worldwide, it is important to document the rare complications associated with it [2]. An unusual complication that can occur is retrograde filling of the afferent limb, causing symptoms like partial bowel obstruction. However, this has not been described in the literature as occurring after SALDS. This paper presents the first 2 cases of retrograde filling of the afferent limb causing chronic nausea that have been seen after laparoscopic SALDS surgery and subsequent management.

Case presentation

Presentation of Case 1

A 41-year-old female with a BMI of 41.2 kg/m² who had gastroesophageal reflux disease (GERD), hyperlipidemia, and hypertension underwent SALDS. Five months post-operatively she presented with new-onset nausea, abdominal fullness, and pain. During an upper gastrointestinal series (UGI), the patient experienced nausea and abdominal pain after the contrast was ingested. The patient's pain correlated with the contrast that primarily filled the afferent limb and dilated the limb (Fig. 1a, b). There was no reflux seen between the small bowel and the stomach on delayed

films. Because of her UGI series, an exploratory laparotomy was performed to identify the cause of her symptoms.

Presentation of Case 2

A 32-year-old female with a BMI of 71.5 kg/m² who had hypothyroidism, polycystic ovarian disease, and hypertension underwent a 2-stage SALDS. The patient had been scheduled for a full SALDS but the loop of bowel would not reach her duodenum during surgery because of a shortened mesentery. Therefore, she was taken back to surgery 6 months after her sleeve for a completion duodenal switch. Six months after her second surgery, she presented with nausea, intermittent vomiting, abdominal pain, and dizziness. An UGI series revealed contrast filling the afferent limb primarily, without reflux into the stomach on delayed films (Fig. 2). Her symptoms of nausea could be reproduced by having the patient drink barium, and when the barium dilated her afferent limb, she became nauseated. After consultation with the patient, the decision was made to return to the operating room.

Perioperative Case 1 and Case 2 management

Exploratory laparotomy (EL) was performed on both patients. In both cases, we found scar tissue that pulled the efferent limb superior to the duodenoileostomy, causing the flow of food and secretions down the afferent limb (Fig. 3a [1,2]). The scar tissue was taken down to allow flow down the efferent limb (Fig. 3b [3,4]). After this, the afferent limb was placed above the duodenoileostomy by tacking the afferent limb with silk sutures to the Sleeve antrum 4 cm

*Correspondence: Daniel Cottam, M.D., Bariatric Medicine Institute, 1046 East 100 South, Salt Lake City, UT 84102.

E-mail: drdanielcottam@yahoo.com

<http://dx.doi.org/10.1016/j.soard.2016.01.018>

1550-7289/© 2016 American Society for Metabolic and Bariatric Surgery. This is an open access article under the CC BY-NC-ND license (<http://creativecommons.org/licenses/by-nc-nd/4.0/>).

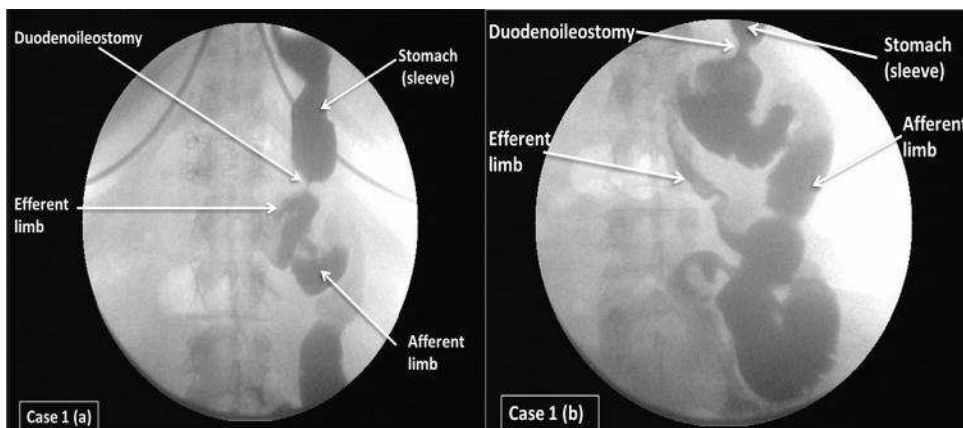


Fig. 1. (a) Image a few minutes after the ingestion of barium contrast shows a dilated afferent limb and very little contrast entering the efferent limb. (b) Image after 30 minutes of the contrast ingestion showing presence of little barium in the distal efferent limb and dilated afferent limb.

proximal to the duodenal ileostomy (DI; Fig. 3b [5]). No complications occurred after either procedure and blood loss was minimal. Total procedure time in both cases was <30 minutes.

Both the patients had an uneventful recovery and were discharged home on day 2. On postoperative day 1 and at 1 month (Fig. 4a, b), a UGI series were performed on both patients, which did not show any leaks or limb obstruction, and contrast drained through the stomach through DI into the efferent limb. Three months postoperatively, both patients are doing well with resolution of all their symptoms.

Discussion

Abdominal adhesions are a common complication of surgery, occurring in a majority of people who undergo abdominal or pelvic surgery. Ninety-four percent of patients develop primary abdominal adhesions after laparotomy [3].

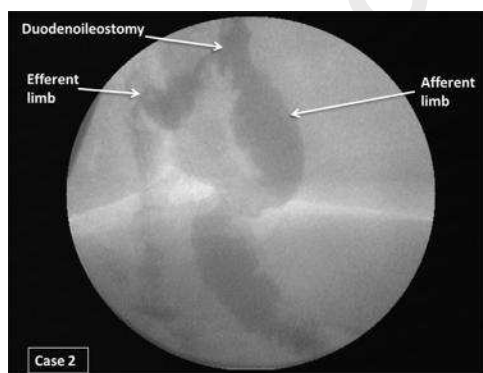


Fig. 2. Highlights preferential filling of the dilated afferent limb with the contrast. Also the efferent limb is much more narrow and filled with little contrast.

However, laparoscopic surgery and microsurgery reduce the risk of adhesion formation, but do not eliminate it entirely [4].

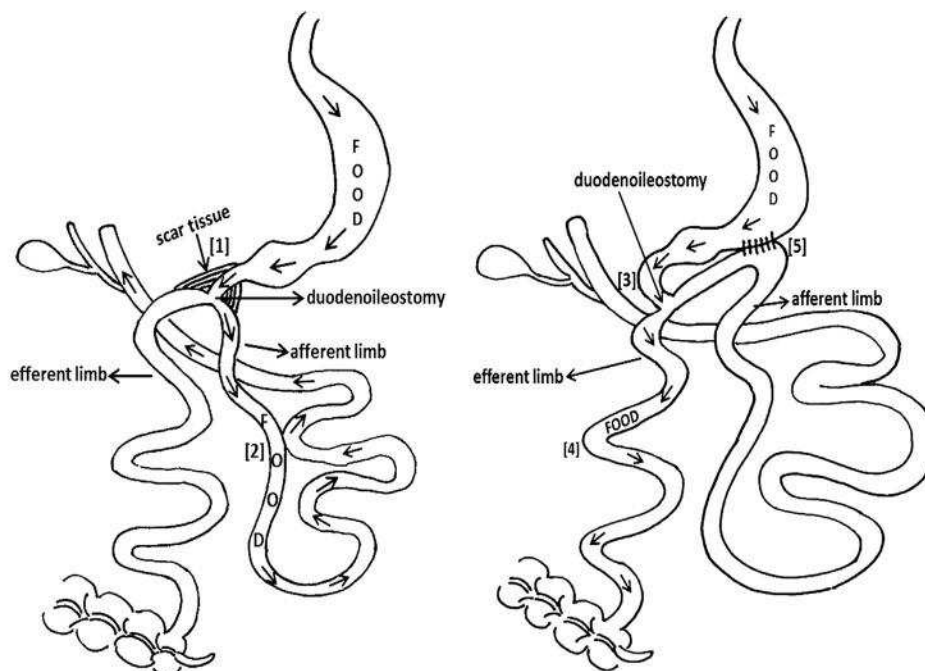
Abdominal adhesions can kink, twist, or pull the intestines out of place, causing an intestinal obstruction [5]. Similarly in these 2 cases, scar tissue was found around DI that pulled the efferent limb superior to DI, causing the food to enter the afferent limb and symptoms like partial bowel obstruction. The symptoms in both of the cases mimic some of the symptoms of afferent loop syndrome except they did not have bilious vomiting (ALS) [6–8]. However, the underlying pathology in ALS is obstruction of the gastrojejunal anastomosis [9,10]. When an UGI was performed in both cases before the EL, filling of afferent limb with contrast suggested a widely patent anastomosis, and the need to revise the DI was eliminated. Eventually in both cases the contrast emptied into the efferent limb without refluxing back to the stomach. Simply by bringing down the scar tissue and tacking the afferent limb above the DI resolved the retrograde filling of afferent limb. Because of these 2 patients, we have made it standard practice to routinely tack the afferent limb to the sleeve 4 cm proximal to the pylorus.

Conclusion

Retrograde filling of the afferent limb after SALDS is rare. The diagnosis is made using fluoroscopy to identify the path of the food and the dilation of the small bowel. The dilated small bowel causes the symptoms, and the treatment is removing the reason for that dilation. In our cases, it was the removal of adhesions distal to the duodenoileostomy that caused resolution of the symptomatic postprandial pain. Tacking the afferent limb to the antrum may help prevent this.

A Schematic representation of the case before management

B After management (Adhesiolysis)



Q5 Fig. 3. Schematic representation of Case 1 and 2, before and after surgery. (a) Shows gravity-pulling secretions and foodstuffs downhill into the afferent loop. (b) Is post-adhesiolysis with the afferent limb tacked superiorly to the sleeve to allow gravity to pull the food and secretion into the efferent limb and away from the duodenoileostomy. Only bile is traveling through the afferent limb now.

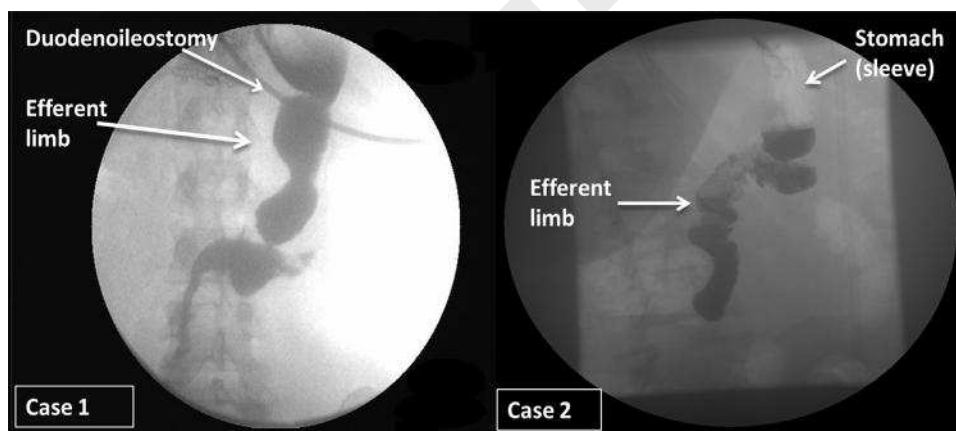


Fig. 4. (Case 1a, Case 2b) Follow-up UGI series at 1 month shows the flow of contrast into the efferent limb, without entering afferent limb.

Disclosures

The authors have no commercial associations that might be a conflict of interest in relation to this article. However, one author did disclose a financial relationship relative to industry that has no bearing on the publication of this article.

References

- [1] Sanchez-Pernaute A, Herrera MA, Perez-Aguirre ME, et al. Proximal duodenal–ileal end-to-side bypass with sleeve gastrectomy: proposed technique. *Obes Surg* 2007;17:1614–8.

- [2] Summerhays C, Cottam D, Cottam A. Internal hernia after revisional laparoscopic loop duodenal switch surgery. *Surg Obes Rel Dis* 2015. In press.
- [3] Menzies D. Peritoneal adhesions. Incidence, cause, and prevention. *Surg Ann* 1992;24:27–45.
- [4] Kavic SM, Kavic SM. Adhesions and adhesiolysis: the role of laparoscopy. *JLS* 2002;6:99–109.
- [5] Lehnert T, Buhl T. Techniques of reconstruction after total gastrectomy. *Br J Surg* 2004;91:528–39.
- [6] Sawyer MAJ, Sawyer EM, Decker RA, et al. Afferent loop syndrome. Available from: www.emedicine.com/med/topic3629.htm.
- [7] Wise SW. Case 24: Afferent loop syndrome. *Radiology* 2000;216:142–5.

256
257
258
259
260
261
262
263
264
265
266
267
268
269
270
271
272
273
274
275
276
277
278
279
280
281
282
283
284
285
286
287
288
289
290
291
292
293
294
295
296
297
298
299
300
301
302
303
304
305
306
307
308
309
310

- 311 [8] Kim HC, Han JK, Kim KW, et al. Afferent loop obstruction after gastric 314
312 cancer surgery: helical CT findings. *Abdom Imaging* 2003;28:624–30. 315
313 [9] Delcore R, Cheung LY. Surgical options in postgastrectomy syn- 316
dromes [Review]. *Surg Clin N Am* 1991;71:57–75.
- [10] Forstner-Barthell AW, Murr MM, Sarr MG, et al. Near-total 314
completion gastrectomy for severe postvagotomy gastric stasis: 315
Analysis of early and long-term results in 62 patients. *J Gastrointest 316
Surg* 1999;3:15–23.

UNCORRECTED PROOF